



PATIENT

Cheyenne Randall

SPECIES

Canine

BREED

Catahoula Mix

SEX

Female Spayed

AGE

8 years

WEIGHT

57lbs

INTERPRETED BY

Maggie Machen
Lamy, DVM
DACVIM (Cardiology)

IMAGING PERFORMED BY

Eduardo Rodriguez
III, RDS

HOSPITAL NAME

Falmouth Animal
Hospital

REFERRING VET

Dr. Switzer

INVOICE

31464

DATE

6/21/23

PRESENTING CLINICAL SIGNS

History: Recheck echo. History chronic valvular disease - Stage B1. Presently, doing well clinically. BP: 130, 130, 134mmHg.

-Pertinent previous echo findings (8/8/22 MML): LA 2.8 cm, LA:Ao 1.4, LV 3.8 cm, normal chamber sizes, moderate MR, mild TR (1.9 m/s).

ECHOCARDIOGRAM FINDINGS

2D, m-mode, color flow and Doppler imaging is available.

Left ventricle: The LV diameter is normal with adequate myocardial function. LV wall thicknesses are normal.

Left atrium: The left atrium is normal.

Mitral valve: The mitral valve is mildly thickened with no prolapse into the left atrial lumen. Moderate eccentric mitral regurgitation with a normal velocity.

Aortic valve/aorta: The aortic valve is normal in morphology and mobility. Normal aortic outflow velocity; laminar flow. No aortic insufficiency.

Right ventricle: Normal right ventricular diameter and morphology indicating no overt evidence of pulmonary arterial hypertension.

Right atrium: Normal RA dimension.

Tricuspid valve: The tricuspid valve appears normal with mild tricuspid regurgitation; normal velocity.

Pulmonic valve/pulmonary artery: The pulmonic valve is normal in morphology and mobility. No pulmonic insufficiency. Normal RVOT velocity; laminar flow.

Pericardium/other: No pericardial or pleural effusion noted. No obvious cardiac masses.

Heart rhythm: ECG reveals a sinus rhythm with an average HR of 150bpm.

2-Dimensional Measurements

| | |
|--------------------|-----|
| Ao diam (cm) | 2.1 |
| LA diam (cm) | 2.9 |
| LA:Ao (Swe) | 1.4 |
| IVS thickness (cm) | 0.8 |
| LVID diastole (cm) | 3.6 |
| PW thickness (cm) | 0.8 |
| LVID systole (cm) | 2.6 |
| FS (%) | 28 |

Doppler Measurements

| | |
|----------------|-----|
| PV Vmax (m/s) | 0.8 |
| AoV Vmax (m/s) | 1.4 |
| MR Vmax (m/s) | 4.9 |
| TR Vmax (m/s) | 2.1 |
| TR PG (mmHg) | 17 |

INTERPRETATION OF THE FINDINGS

Chronic degenerative valve disease persists with overall stability. Moderate mitral and mild tricuspid regurgitation are unchanged with stable left and right heart dimensions. No concurrent issues have developed.

Given these findings, no medications are indicated. Continued assessment of progression in the future will help predict long term prognosis, which is highly variable at this stage (B1).



PATIENT

Cheyenne Randall

SPECIES

Canine

BREED

Catahoula Mix

SEX

Female Spayed

AGE

8 years

WEIGHT

57lbs

INTERPRETED BY

Maggie Machen Lamy, DVM
 DACVIM (Cardiology)

IMAGING PERFORMED BY

Eduardo Rodriguez III, RDS

HOSPITAL NAME

Falmouth Animal Hospital

REFERRING VET

Dr. Switzer

INVOICE

31464

DATE

6/21/23

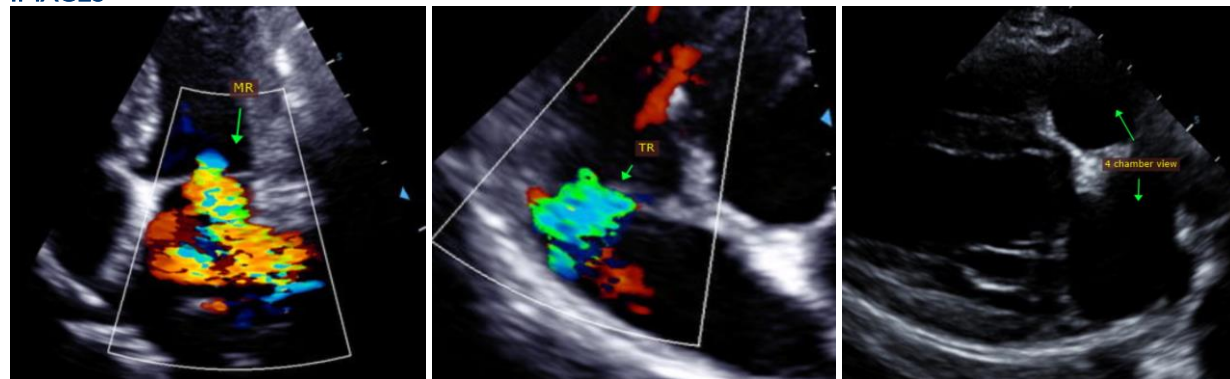
RECOMMENDATIONS

- No cardiac medications are clearly indicated.
- Omega fatty acid supplementation and mild salt restriction may be of some long-term benefit.
- Anesthetic risk is considered mild if needed. Cardiac protective drug choices (opioid/benzodiazepine premedication, propofol or alfaxalone induction, isoflurane gas) are recommended. Pre-oxygenate for 5-10 minutes prior to induction. Monitor for arrhythmias, hypotension, and hypoxia both intra and post-operatively and intervene as necessary. Mild IV fluid restriction is recommended to avoid fluid overload. Avoid heart rate stimulating drugs such as atropine unless clinically indicated.
- Monitor for development of a cough, labored breathing, exercise intolerance or collapse episodes.

PLAN

- Recommend conservative monitoring with a recheck echocardiogram in 6-9 months, sooner if any development of clinical signs.

IMAGES



The information and recommendations provided are based on the images presented by the referring veterinarian. No evaluation can be communicated regarding pathology that was not visible in the image/video clips provided.

Thank you for this referral. This report was generated using transcription software, and minor dictation errors may be present. If the clinical or image interpretation does not parallel your findings or if I can be of any further assistance, please contact me.

Maggie Machen Lamy, DVM
 Diplomate of the American College of Veterinary Internal Medicine (Cardiology)
 info@sonopath.com

Echocardiogram performed by: Eduardo Rodriguez III, RDS
 Pet Animal Ultrasound Service (4paus.com)